Treatment efficiency of combination therapy using diminazene aceturate and quinapyramine sulfate for a dourine horse in Mongolia

Batbold Davkharbayar[a], Batdorj Davaasuren[a], Sandagdorj Narantsatsral[a], Banzragch Battur[a], Myagmarsuren Punsangtsogvoo[a], Badgar Battsetseg[a], Daiki Mizushima[b], Noboru Inoue[b], Keisuke Suganuma[b]

[a] Institute of Veterinary Medicine, Monoglia
[b] OIE Reference Lab. (Surra), National Research center for Protozoan Diseases, Obihiro Univ. of Agricult. & Vet. Med., Japan

20181202 - 4 3rd International Conference on NTTAT @North-West Univ., Pochefstroom, SA

Dourine and *Trypanosoma equiperdum*

Giemsa stained *T. equiperdum*
(Suganuma *et al.*, 2016)

Swelling of penis

Dourine, which is cased by *T. equiperdum* infection, is a sexually transmitted disease of equidae.

T. equiperdum is a primarily tissue parasite (genital organ, CSF, skin lesion), therefore, it is very rare to observe trypanosomes in bloodstream.

Dourine is listed as an international important disease by world organization for animal health (OIE).

However, there are not established well authorized treatment strategy and the OIE recommended stamping-out policy in dourine free countries.

Clinical signs of dourine

T. equiperdum are transmitted by coitus and primary parasitize on genital organ mucosa → **Clinical signs around genital organ**

Swelling of the penis

Accumulation of smegma

Clinical signs of dourine

T. equiperdum invade into tissue and parasitize in cerebrospinal fluid (CSF)
→ **Neurological symptoms**

Facial nerve paralysis, imbalance nose shape

Horse in Mongolia and our research activities

Mongolia is the 5th greatest country for horse bleeding (>3.5 million horses, FAO, 2016).

Horse is important as...

- Economic value (Expensive!)
- Transportation
- Livestock product (milk and meat)
- Nomadic cultural, spiritual, custom...

MIAT
MONGOLIAN AIRLINES

A huge economic loss, which is caused by trypanosomosis, in horse production has been estimated in Mongolia, however, effective counter measures for the disease have not been initiated due to the lack of disease information.

Our researches from 2015 ~

- Epidemiological study in whole Mongolia
- Isolation and cultivation of trypanosome
- Treatment of clinical cases

Epidemic situation of horse trypanosomoses (surra and dourine) in Mongolia

Sero-positive ratio using rTeGM6-based ELISA

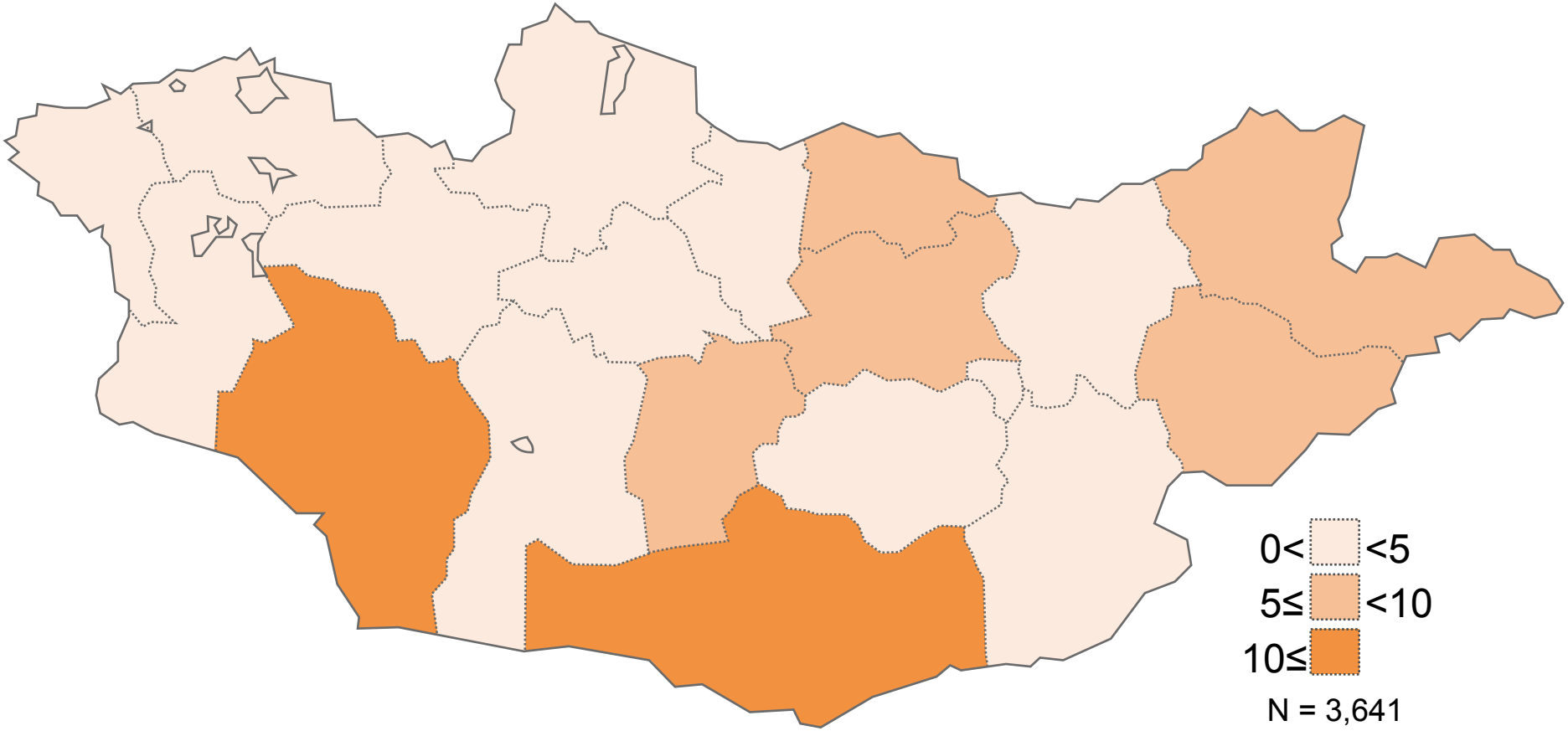

4.8% (4.1 – 5.5 %, 95%CI) of horse serum samples were positive for horse trypanosomoses in Mongolia.

Mizushima *et al.*, under review

Five new *T. equiperdum* isolates from Mongolia

Strain name	Isolated date	Sex, Age	Isolated lesion	Farm location (aimag)	Ref. & Remarks
IVM-t1	April, 2015	male, 7	Urogenital tract swab	Töv	Suganuma & Narantsatsral *et al.*, 2016
IVM-t2	April, 2016	male, ?	Urogenital tract swab	Töv	
IVM-t3	December, 2016	female, 9	Cerebrospinal fluid (CSF)	Dundgovi	
IVM-t4	January, 2017	male, 8	Urogenital tract swab	Hentii	
IVM-t5	March, 2017	Thoroughbred stallion, 6	Urogenital tract swab	Töv, Batsumber county	Horse imported from Russia

Suganuma *et al.*, unpublished data

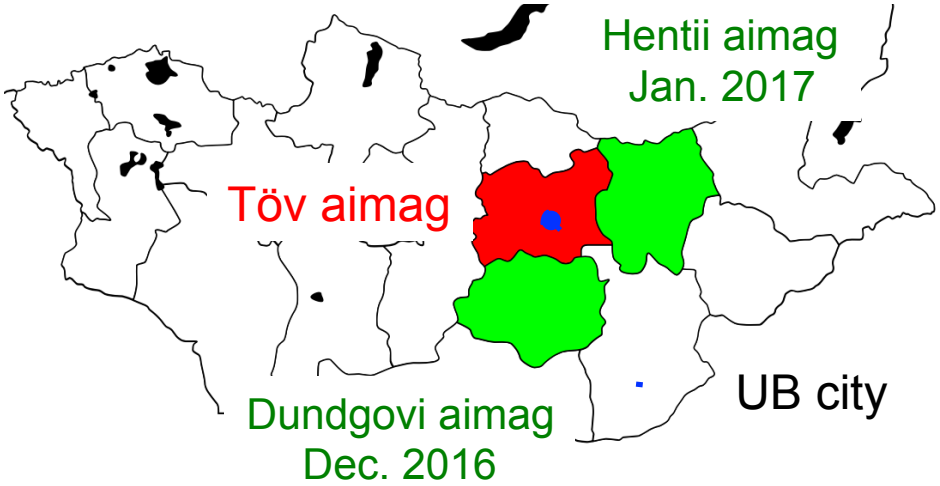

Five new *T. equiperdum* strains were directly isolated from urogenital tract or cerebrospinal fluid and culture adapted using soft agarose medium.

Summary of treatment strategy

The stumping-out policy might not be suitable for nomadic countries.

Object the study:

Evaluation of treatment efficacy of diminazene aceturate and quinapyramine sulfate for establishment of dourine cases treatment.

Treatment strategy

- ✓ Diminazene aceturate (DA): 3.5 mg/kg, three times, 24h interval, sc.
- ✓ Quinapyramine sulfate (QS): 3 mg/kg, twice per week, sc.

Evaluation of treatment efficacy

- ✓ Body condition and clinical signs
- ✓ Blood parameters
- ✓ Microscopic observation of blood and urogenital tract mucosa
- ✓ PCR using blood and urogenital tract mucosa
- ✓ Serological analyses by ICT and ELISA

Clinical case of the dourine stallion

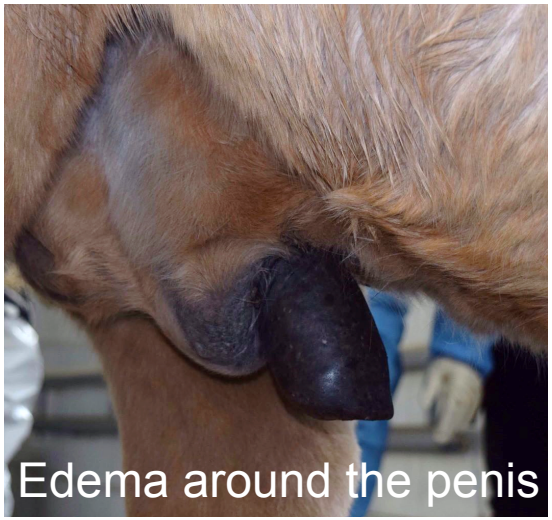

The eight years old stallion with characteristic dourine signs.

Davkharbayar and Davaasuren *et al.*

Two month after the treatment

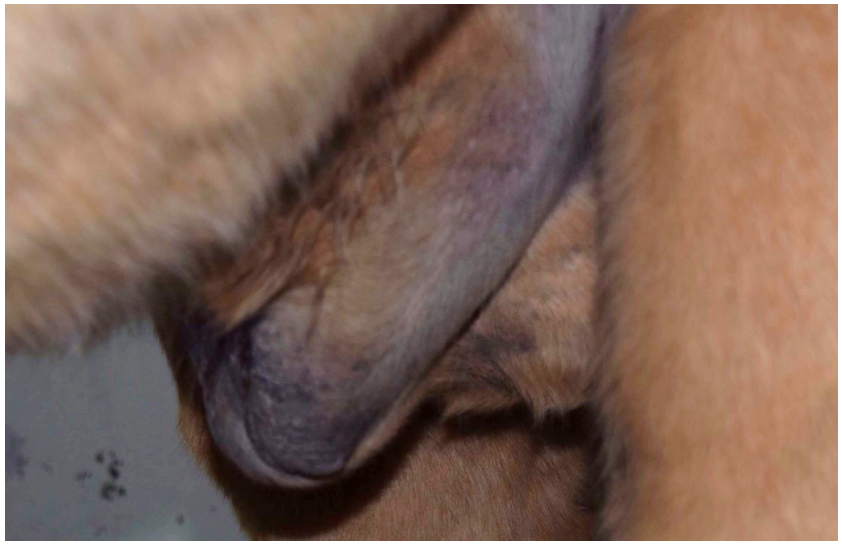

The characteristic signs were disappeared.

Davkharbayar and Davaasuren *et al.*

Trypanosome was detected in genital mucosa

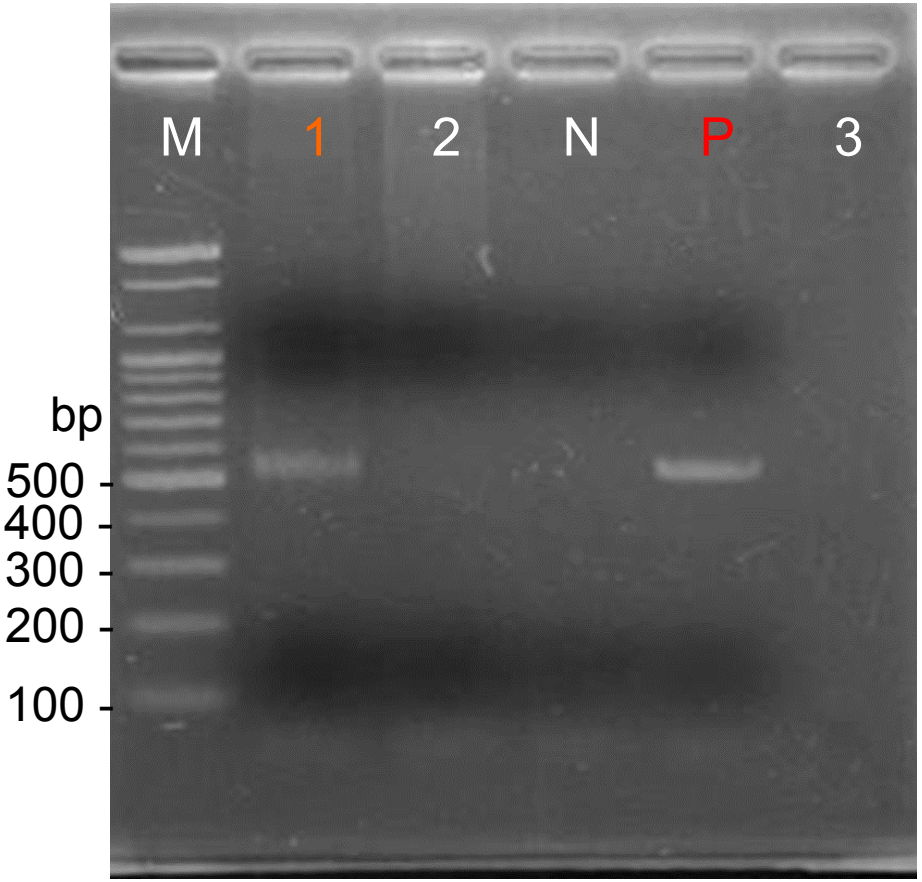

P: Positive control
N: Negative control
1: Genital organ sample, before treatment
2: Blood sample, before treatment
3: Genital organ sample, after treatment
(KIN Primer sets, Desquesis *et al.*, 2001)

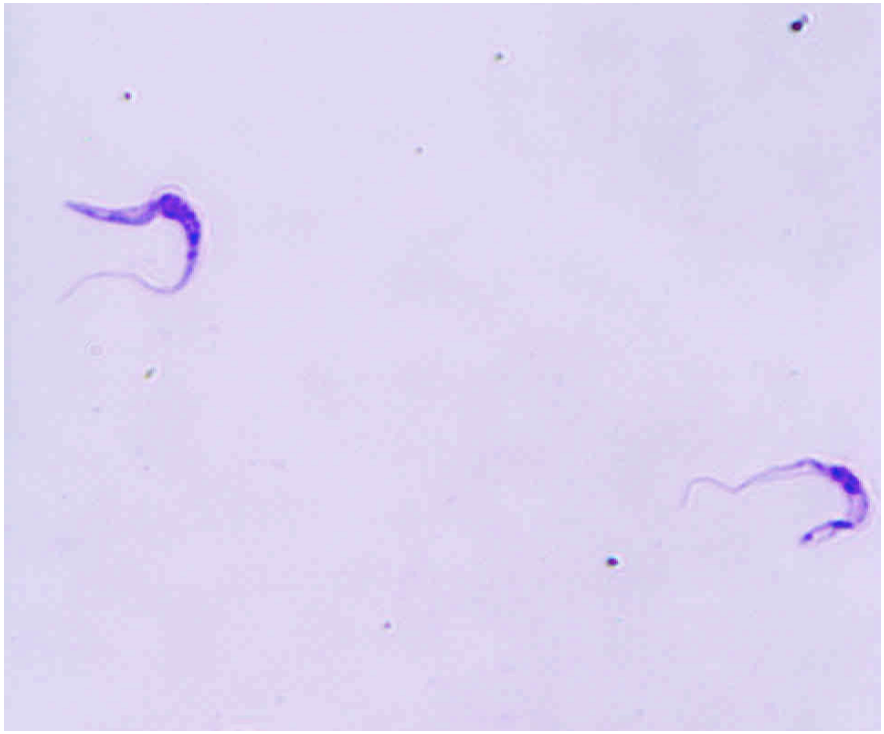

Giemsa stained trypanosomes isolated from genital organ swab.

Trypanosomes were detected in genital organ sample, but not detected in blood.

Davkharbayar and Davaasuren *et al.*

T. equiperdum IVM-t5 strain was established

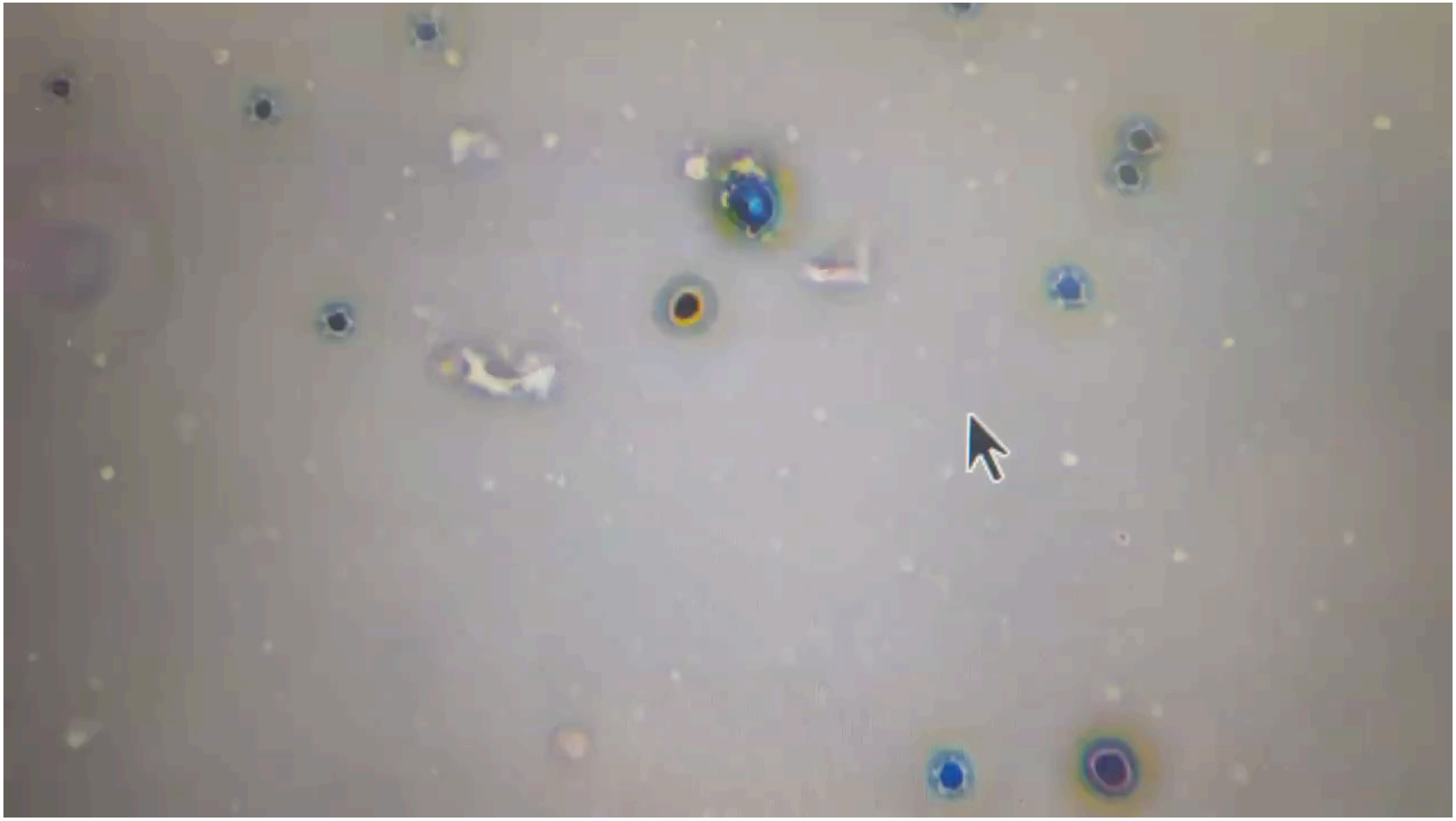

The culture-adapted *T. equiperdum* IVM-t5 showed RoTat1.2 VSG negative (A marker for *T. evansi* type A)

Davkharbayar and Davaasuren *et al.*

Serological analyses using rTeGM6 antigen

Immunochromatograhic test (ICT)



P: Positive control
N: Negative control
1: Before the treatment
2: Two weeks after the treatment
3: One months after the treatment
4: Two months after the treatment
5: three months after the treatment
6: Six months after the treatment
7: One year after the treatment.

Antibody titer analyzed by ELISA

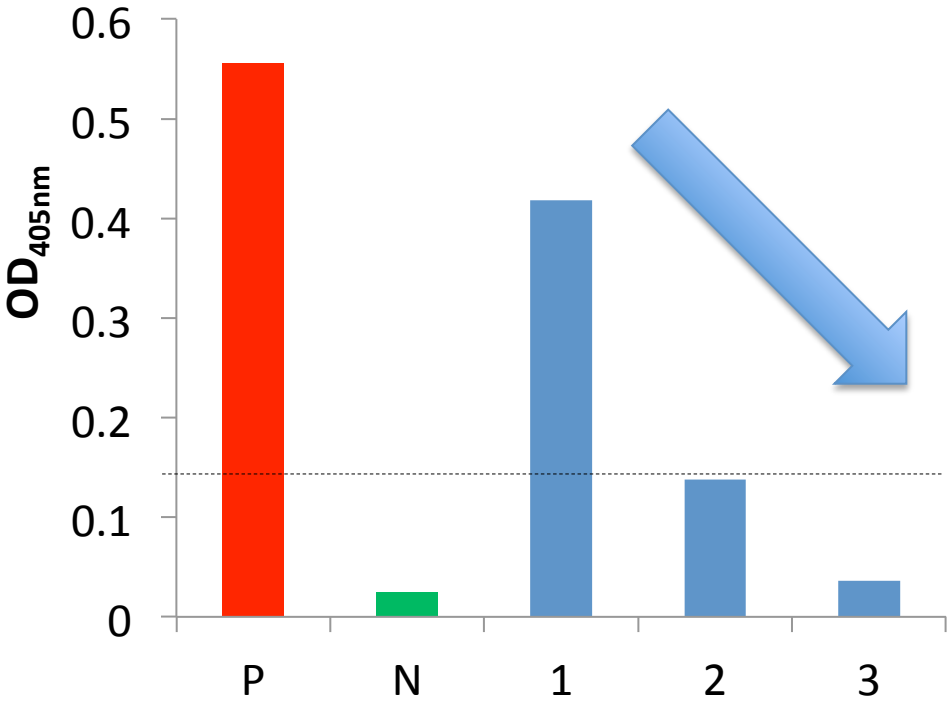

P: Positive control
N: Negative control
1: Before the treatment
2. Two months after the treatment
3: Six months after the treatment
Dot line: cut off (OD = 0.15)

Davkharbayar and Davaasuren *et al.*

A dourine suspected stallion case was identified.

Before the treatment...

- Edema around the penis, accumulation of smegma, and paralysis were observed in the stallion.
- Trypanosomes were found in genital organ sample, but not in blood.
- RoTat1.2 VSG PCR was negative.

→ This case was clinically, parasitologically, and molecularly diagnosed as dourine and *T. equiperdum*.

After two month treatment by DA and QS...

- Clinical symptoms were disappeared.
- Trypanosomosis was not relapsed until now (≈ 2 years).
- *T. equiperdum* were not detected in genital organ sample.

→ DA and QS treatment may be effective for early stage of dourine.

- rGM6-based serological tests also shows negative.

→ rGM6-based serological tests may apply for the diagnosis of dourine.

For establishment of dourine treatment strategy, we have to treat and analyze more numbers of dourine case using DA and QS in the further study.

Acknowledgements

Institution of Veterinary Medicine, Mongolia

National Research Center for Protozoan Diseases, Japan

Mongolian farmers and local veterinarians

JICA/AMED SATREPS, JSPS, OIE

SATREPS
Science and Technology Research Partnership for Sustainable Development Program

Obihiro University of Agriculture and Veterinary Medicine

МОНГОЛ УЛС
МАЛ ЭМНЭЛГИЙН ХЭЛТЭС

World Organisation for Animal Health