

## CHAPTER 3.2.1.

# ACARAPISOSIS OF HONEY BEES (INFESTATION OF HONEY BEES WITH *ACARAPIS WOODI*)

---

### SUMMARY

*Acarapisosis* is a disease of the adult honey bee *Apis mellifera* L. and other *Apis* species. It is caused by the tarsonemid mite, known as the tracheal mite, *Acarapis woodi*. The adult female mite is approximately 150 µm in size, and is an internal parasite of the respiratory system, living and reproducing mainly in the large prothoracic tracheae of the bee. Sometimes they are also found in the head, thoracic and abdominal air sacs and can also be found at the base of the bee's wings. Mites feed on the haemolymph of their host.

Pathogenic effects in infected infested bees depend on the number of mites within the trachea. The mites can cause both mechanical injuries and physiological disorders consequent to the obstruction of air ducts, lesions in the tracheal walls, and the depletion of haemolymph. As the mite population increases, the tracheal walls, normally white and translucent, become opaque and discoloured with blotchy black areas, probably due to melanin crusts.

Some strains of bees are less susceptible to *A. woodi* infestation. The mortality rate in infested bees may range from moderate to high. Early manifestations of infestation normally go unnoticed, and only when infestation is heavy does it become apparent. This is usually in spring. The mite spreads by direct contact. Generally, adult bees less than 4 days post-emergence are more susceptible. Reproduction occurs within the tracheae of adult bees, where female mites may lay up to 14 eggs. There are usually more females than males, though the ratio can vary. Development takes 11–12 days for males and 14–15 days for females.

**Detection and identification of the agent:** The mites are detected only by laboratory methods either by microscopy, or molecular detection.

For microscopy, the mites need to be observed inside the tracheae or removed from them to be observed microscopically. The thoraces of suspect bees are dissected to expose the tracheae. Each trachea is examined under a dissecting microscope (×40–60), where the mites will be seen through the transparent wall as small oval bodies.

Alternatively, larger samples of suspect bees can be ground or homogenised in water, followed by coarse filtration of the suspension, and centrifugation. The deposit is treated with undiluted lactic acid for 10 minutes. This is then mounted for microscopic examination.

The mites may be stained by histological techniques so that they can be observed within the bee trachea. The tracheae are separated out, cleared with 5–10% potassium hydroxide, and stained with 1% methylene blue. This is the best method (thoracic disc method) for large numbers of samples.

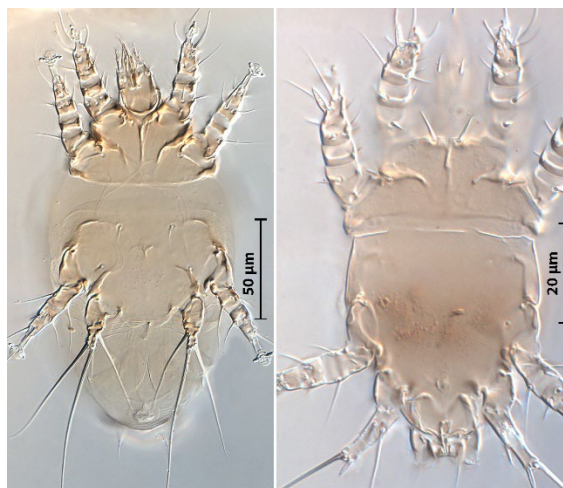
For molecular detection, both conventional and real-time polymerase chain reaction (PCR) methods that detect the cytochrome *I* oxidase gene of *Acarapis woodi* can be used. Amplicons from the conventional PCR must be sequenced to provide confidence in the detection of *A. woodi*, as distinct from the related mites *A. dorsalis* and *A. externus*. A sample of 105 bees is obtained from a colony and their abdomens removed and discarded. Seven separate DNA extractions are performed, with 15 bees each, where bees are homogenised in lysis buffer and the extracted DNA subjected to PCR. The real-time PCR is useful when large numbers of samples are processed. False-positive detections of *A. externus* and *A. dorsalis* may be possible, and confirmatory testing by microscopy is required.

**Serological tests:** Serological tests are not available.

**Requirements for vaccines:** There are no vaccines available.

## A. INTRODUCTION

Acaraposis (syn. Acariosis or acarine disease) is a disease of the adult honey bee *Apis mellifera* L. and other *Apis* species, caused by the microscopic tarsonemid mite *Acarapis woodi* (Rennie). The adult female mite is approximately 150 µm in size (Figure 1) and is an internal parasite of the respiratory system. These tracheal mites enter, live and reproduce mainly in the large prothoracic tracheae of all bees, feeding on the haemolymph of their host. Sometimes they are also found in the head, thoracic and abdominal air sacs (Giordani, 1965; Wilson et al., 1997).



**Fig. 1.** *Acarapis woodi* (Rennie). Ventral views of adult female (left) and adult male.

The pathogenic effects on individual bees depends on the numbers of mites within the tracheae and are attributable both to mechanical injuries and physiological disorders consequent to the obstruction of the air ducts, lesions in the tracheal walls, and to the depletion of haemolymph. As the parasite population increases, the tracheal walls, which are normally whitish and translucent, become opaque and discoloured with blotchy black areas, probably due to melanin crusts (Giordani, 1964).

Colony loss rates may vary, but these losses can be very high. When the mite first establishes in bee populations with no prior exposure. Early signs of infestation may go unnoticed, except for a slow dwindling in the colony size. Only when infestation is heavy does it become apparent. This is generally in spring after the winter clustering period when the mites have bred and multiplied undisturbed in the longer-living winter bees. Some races of bees, such as Buckfast bees (Brother Adam, 1968) and some hygienic strains, are less susceptible to *A. woodi* infestation. Mites spread from one bee to another by direct contact. Generally, only young adult bees (under 4 days post-emergence), are susceptible. Attempts to rear *A. woodi* artificially have had limited success (Bruce et al., 1991). Controlled infestation of immature bees can be achieved (Giordani, 1970) and has allowed for the determination of mite life cycle, host preference and host resistance, and the effect of the mites on adult bees. Reproduction occurs within the tracheae of adult bees, where female mites may lay 8–20 eggs. There are 2–4 times as many females as males; development takes 11–12 days for males and 14–15 days for females.

There are no reliable clinical signs for the diagnosis of acaraposis as the signs of infestation are not specific and the bees behave in much the same way as bees affected by other diseases or disorders. They crawl around in the front of the hive and climb blades of grass, unable to fly. Dysentery may be present. Heavy mite infestations in winter months affects the ability of colonies to regulate their cluster temperature leading to chilling, which can be a significant cause of death Otis & Scot-Dupree (1992).

## B. DIAGNOSTIC TECHNIQUES

Table 1. Test methods available and their purpose

Method	Purpose					
	Population freedom from infestation	Individual animal freedom from infestation prior to movement	Contribute to eradication policies	Confirmation of clinical cases	Prevalence of infestation – surveillance	Immune status in individual animals or populations post-vaccination
<b>Agent detection and identification</b>						
Microscopy – bee dissection	+++	–	+++	+++	++	–
Microscopy – bulk sample	+	–	+	++	+	–
Conventional PCR	+	–	+	++	+	–
Real-time PCR	++	–	++	++	++	–

Key: +++ = recommended for this purpose; ++ recommended but has limitations; + = suitable in very limited circumstances; – = not appropriate for this purpose.  
PCR = polymerase chain reaction.

### 1. Detection and identification of the agent

Acarapisosis can be detected only in the laboratory using microscopic examination or by molecular detection. The number of bees sampled determines the detection threshold of the method. It has been shown that a 1 to 2% rate of infestation can be detected by sampling 50 bees. Sequential sampling data are available (Frazier *et al.*, 2000; Tomasko *et al.*, 1993). The best time to take bee samples is in the early spring or late autumn when *Acarapis* populations are high. Visualisation of mites is easier in older bees, which have more mites. Even though drones can be found to have a higher abundance of mites per bee (Dawicke *et al.*, 1992) the most significant caste affected by *A. woodi* is the worker bee population, which far outnumber drones and are present in the colony throughout the entire year, including the seasons that a colony is most vulnerable, being winter and early-spring.

#### 1.1. Microscopy – dissection of individual bees

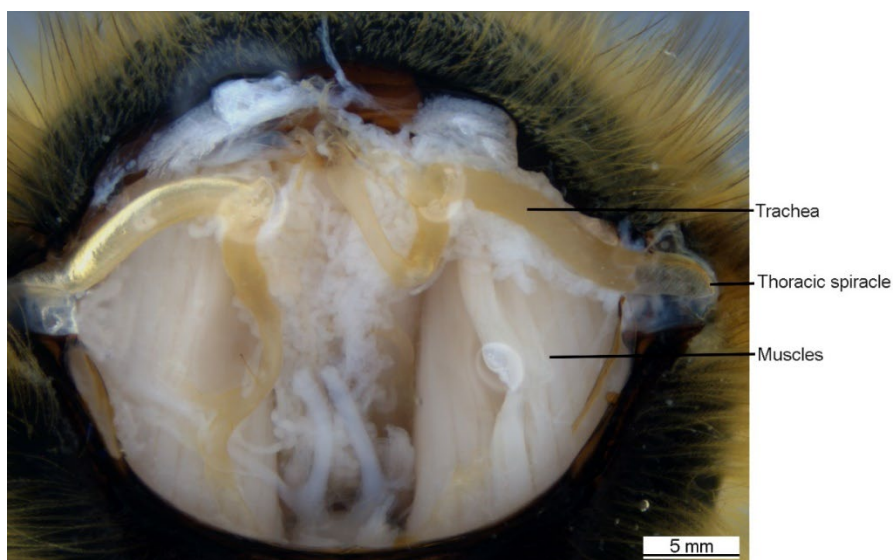
Microscopy provides the simplest and most reliable technique for the laboratory diagnosis of acarapisosis, allowing for the detection of early infestations and enabling the infestation rate to be established. Even light infestations can be detected using a dissecting microscope (40–60×). Only in very exceptional instances will it be necessary to employ higher magnifications to make a diagnosis. However, detection methods using microscopy are demanding techniques and require lots of time, especially when a large number of samples is to be processed.

A sample of 50 bees (see above) should be collected from the colony. These are mainly bees crawling and unable to fly, found within about 3 metres of the front of the hive. This is preferable to random collection from within the colony. The bees may be living, dying, or dead. Live bees must first be euthanised with ethyl alcohol or in a deep freezer (–20°C) for up to 48 hours; sampled dead bees should not have been dead for more than 2–3 days unless kept at 4°C for up to 4 weeks or –20°C several months. They may be preserved indefinitely in a preservative such as Oudemans' solution: glacial acetic acid (80 ml); glycerol (50 ml); 70% ethanol (870 ml).

##### 1.1.1. Test procedure: direct preparation (Milne, 1948; Lorenzen & Gary, 1986)

- i) Place bee under a dissection microscope on their backs and hold using forceps or insect pins, then remove the head and first pair of legs from the thorax using a blade.

- ii) Remove the prothoracic sclerite (collar) using forceps.
- iii) The two thoracic tracheal trunks in the mesothorax are exposed (Figure 2). Positive diagnosis consists of either the presence of melanisation of one or both tracheae or, in light infestation, of the presence of oval translucent bodies (eggs etc.) easily seen within the tracheae.
- iv) For further microscopic examination, especially for confirmation of light infestation, remove the tracheae and put them onto a slide, with a drop of Hoyer's medium: distilled water (50 mm), chloral hydrate (200 g), glycerine (20 ml) and crystalline gum arabic (30 g). Under the microscope at 100× magnification the adult mites as well as their individual stages of development can be recognised.

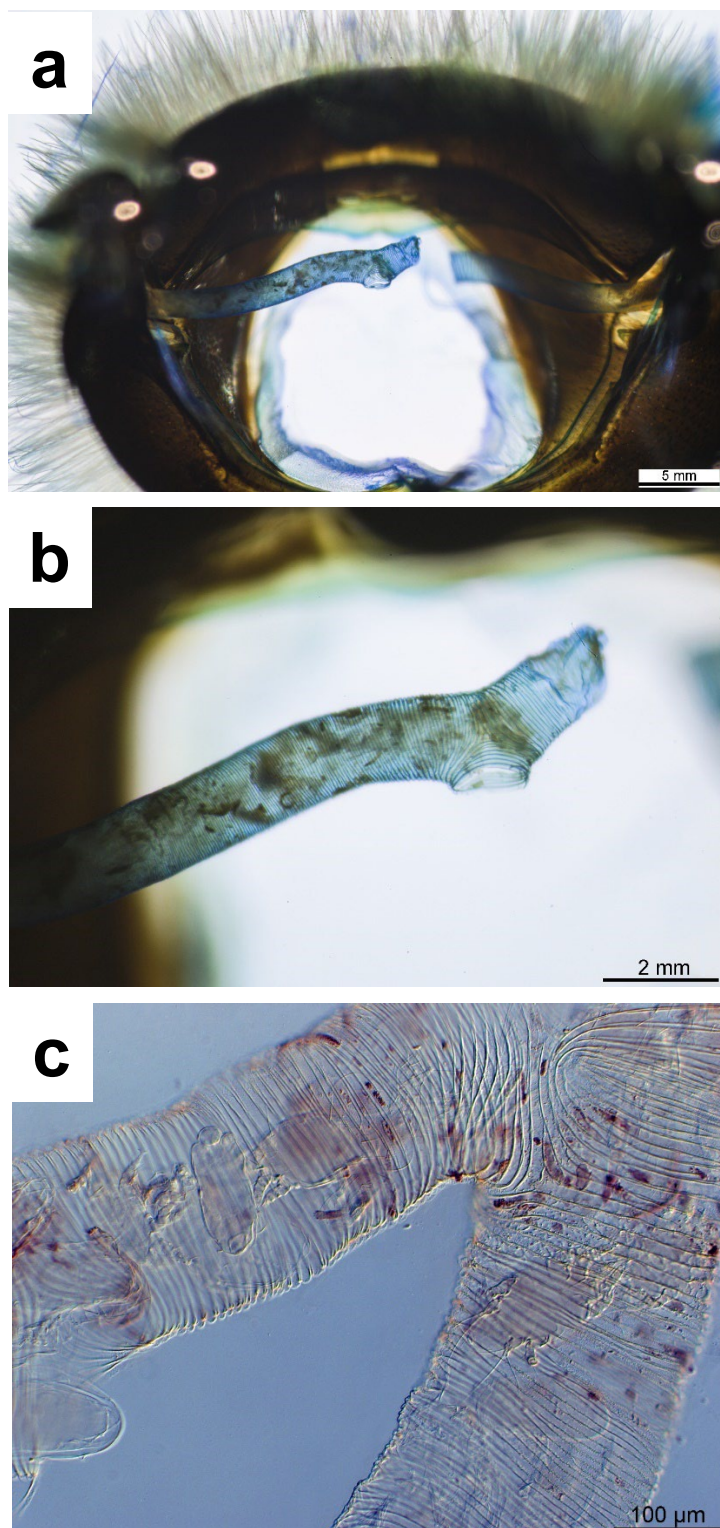


**Fig. 2.** *The first thoracic pair of tracheae exposed in the mesothorax of a bee (*Acarapis woodi* are not present in this specimen).*

#### 1.1.2. Test procedure: thoracic disc method (Peng & Nasr, 1985; Sammataro *et al.*, 2013)

- i) Lay bees on their backs and hold with forceps.
- ii) Remove the heads and forelegs using a second pair of forceps. This exposes the tracheae in the mesothorax.
- iii) Using a sharp scalpel or razorblade, cut through the thorax in front of the middle pair of legs to create a 1–1.5 mm thin thoracic section (disc). Many thoracic discs can be prepared in this way and kept chilled at 4°C, or frozen, before further preparation.
- iv) Muscle is cleared from the thoracic disc by heating at 60°C in a 5–10% solution of potassium hydroxide (KOH) for 2 hours.
- v) Debris is removed by rinsing the sections under running water in a fine sieve.
- vi) The sections are returned to a 5–10% solution of potassium hydroxide and heated to 60°C for 1 hour. The sections will become transparent in the centre leaving only the sclerotised tergites and main tracheal trunks.
- vii) The sections are washed gently under running water in a fine sieve to remove any residual debris.
- viii) Sections are transferred to a petri dish containing distilled water and a few drops of 1% aqueous methylene blue; staining for 5 minutes.
- ix) When staining is complete, remove the sections from the staining solution and transfer them to a dissecting microscope for visual assessment. Examine at 20–40× magnification, with illumination from below. Mites are easily seen through the transparent wall as small, oval bodies (Figure 3).

- x) The sclerotised tergites can be torn away using forceps to make the trachea more visible. Trachea can then be mounted on a glass slide and transferred to a compound microscope for more detailed visualisation of mites (ca. 100× magnification; Figure 3C).



**Fig. 3.** (a) Presence of *Acarapis woodi* in tracheae of honey bee, revealed using the thoracic disc method and a dissecting microscope; (b) under higher magnification; (c) presence of *Acarapis woodi* in tracheae viewed using a compound microscope.

## 1.2. Microscopy – bulk sample preparation and screening based on mite morphology (Colin *et al.*, 1979)

A sample of 200 bees is collected at random from the suspect colony. The wings and legs of each bee are removed from the thorax, and the bodies are pooled in a 100 ml container that has been one-quarter filled with water. This suspension is homogenised three times, each time for several seconds, in a homogeniser at 10,000 rpm with the addition of more water. The resulting suspension is strained through a sieve (mesh 0.8 mm) and the sieve is rinsed with water to a final volume of approximately 50 ml. The filtrate is centrifuged at 1500 *g* for 5 minutes and the supernatant fluid is discarded. A few drops of undiluted lactic acid solution are added to the debris of the deposit, which will contain the mites. This is left for 10 minutes to allow the muscle fibres to dissolve, and is then mounted under a cover-slip for microscopic examination. This technique is quicker than dissection, but is less accurate. External mites *A. externus* and *A. dorsalis*, both of which are morphologically similar to *A. woodi*, are often found on the neck and thorax of healthy bees and can very easily be mistaken for *A. woodi* (Delfinado-Baker *et al.*, 1982). It seems, however, that they do not cause any serious threat to bees or beekeeping. This method should therefore only be chosen if all that is required is a rough estimation of the degree of infestation in a region. It is not suitable for detection of an incursion into a region.

## 1.3. Molecular detection of *Acarapis woodi* infestation of *Apis mellifera*

Detection of *Acarapis woodi* infestation in bee colonies using PCR methods is faster and more efficient than microscopy, and may be more sensitive. However, caution must be exercised when interpreting the results of PCR testing due to the genomic similarities between *A. woodi* and the close-relatives *A. dorsalis* and *A. externus*, which for certain rare genotypes may lead to false-positive detections of *A. woodi*. Positive detections require confirmation by microscopy.

### 1.3.1. Extraction of nucleic acid from *Apis mellifera* for detection of *Acarapis woodi* (Delmiglio *et al.*, 2016)

A conservative sample size of 105 bees per colony should be used, although smaller sample sizes can be used if it is expected that high mite infestations are present. A maximum number of 15 bees can be used in a single DNA extraction, ensuring that a single bee with a low-level of infestation (<10 mites) can be detected. A minimum of seven DNA extractions are required to test a colony sample of 105 bees.

- i) 105 bees are shaken in warm water on an orbital mixer for 20 minutes to dislodge external mites.
- ii) The abdomen of each bee is removed using a clean scalpel and the heads and thoraxes are placed into filter-mesh grinding bags to separate exoskeleton fragments after maceration. 0.5 ml of a nucleic acid lysis buffer is added per bee; commercial nucleic acid extraction buffers that contain chaotropic salts e.g. guanidine thiocyanate, are available for DNA extraction.
- iii) Bees are macerated in the lysis buffer using a grinder or paddle blender, and 600 µl of lysate is placed into a clean reaction tube with 30 µl proteinase K (concentration) and incubated at 65°C for 30 minutes with mixing
- iv) The lysate is then subjected to centrifugation at 8000 *g* for 1 minute.
- v) The resulting supernatant is aspirated and subjected to DNA extraction; commercial DNA extraction kits are available and selected kits should be validated for diagnostic purposes before use e.g. magnetic-bead particle separation methods, or affinity column-based separation.

### 1.3.2. Conventional PCR (Evans *et al.*, 2007; Kojima *et al.*, 2011; Navajas *et al.* 1996)

Conventional PCR approaches for the detection of *Acarapis woodi* are available but require confirmatory sequencing of the amplicons to provide confidence of detection. Nucleic acid extraction can be performed using the method described in Section B.1.3.1, but alternative DNA extraction techniques have been used for the conventional PCR approaches, including extraction of DNA from individual *Acarapis* sp. mites.

Evans *et al.* (2007) use amplification of the mitochondrial cytochrome oxidase I gene (Navajas *et al.*, 1996) to detect *Acarapis* sp., with sequencing of the amplicon to provide species-level determination of *A. woodi*, *A. externus* and *A. dorsalis*. Nested-PCR primers are also available that may enhance the sensitivity of detection.

**Table 2. PCR primer sequences**

Primer/Probe	Sequence (5' → 3')	Amplicon length*	Region
MitCOI.F	AGT-TTT-AGC-AGG-AGC-AAT-TAC-TAT	559 bp*	Cytochrome oxidase I
MitCOI.R	TAC-AGC-TCC-TAT-AGA-TAA-AA		
AcwdCOI.F	TCA-ATT-TCA-GCC-TTT-TAT-TCA-AGA	377 bp*	Cytochrome oxidase I
AcwdCOI.R	AAA-ACA-TAA-TGA-AAA-TGA-GCT-ACA-ACA		

\*Inferred from primer alignment with genbank accessions, KX790788 and LC512730.

If using a commercial PCR kit, the required reagents may already be included. Check and follow the manufacturer's instructions.

PCR reactions using MitCOI primers (Evans *et al.*, 2007; Navajas *et al.*, 1996) are set up in a total volume of 25 µl, as follows:

- i) 1–5 µl template DNA (see Section B.1.3.1);
- ii) 0.2 µM forward (MitCOI.F) and reverse primer (MitCOI.R);
- iii) 1 mM dNTPs;
- iv) 2 mM MgCl<sub>2</sub>;
- v) 1 U of Taq polymerase in the appropriate PCR buffer

Using the following thermocycling conditions: 30 cycles of 94°C (1 minute), 52°C (1 minute), and 72°C (1 minute); and a final cycle of 72°C (5 minutes).

Subsequent nested-PCR on the amplicon using the same reaction conditions but with internal forward (AcwdCOI.F) and reverse (AcwdCOI.R) primers may provide greater sensitivity for detection, where Evans *et al.* (2007) report this nested-PCR approach can be used to determine the *Acarapis* species of a single isolated mite. The molecular weights of the amplicons can be determined by electrophoresis in a 0.8% agarose gel and staining with a DNA-intercalating dye. Amplicon size is not sufficient for *Acarapis* species-level assignment, and sequencing of the amplicon with comparison to reference sequences on genetic databases is required to be confident when assigning a detection to one of the three *Acarapis* species.

Amplicons can be purified using a commercially-available method, such as resin-binding or enzymatic-digestion of <100 bp fragments, and then amplicons sequenced using Sanger-method, or an alternative sequencing approach. Amplicon sequence should be aligned with *Acarapis* sp. sequences from genetic databases and a phylogenetic tree constructed to determine the closest relative.

An alternative series of primers is available for the detection of *Acarapis* sp. (Kojima *et al.*, 2011) but they have not been trialled against *A. dorsalis* and therefore have unknown utility in distinguishing *A. dorsalis* from *A. woodi*.

### 1.3.3. Real-time PCR (Delmiglio *et al.*, 2016)

Specific detection of *A. woodi* using real-time PCR can be achieved by amplification of a 113 nt single variable region within the mitochondrial cytochrome oxidase I gene (COI) (Delmiglio *et al.*, 2016). A small proportion of genetically different *A. externus* have been reported to cross-react

with this assay. Therefore, if a real-time PCR positive is recorded in a population of bees where *A. woodi* has not been reported before, then a confirmatory test using microscopy should be performed.

**Table 3. Primer sequences for real-time PCR**

Primer/Probe	Sequence (5'→ 3')	Amplicon length	Region
aw_F1-flap	AAT-AAA-TCA-TAA-TGA-TAT-CCC-AAT-TAT-CTG-AGT-AAT-G	113 bp	Cytochrome oxidase I
aw_R3	AAT-ATC-TGT-CAT-GAA-GAA-TAA-TGT-C		
aw_LNAprobe	6-FAM-ACC[+T]GT[+C]AA[+T]CC[+A]CCTAC-BHQ1		

\*[+] locked nucleic acid bases

If using a commercial PCR kit the required reagents may already be included. Check and follow the manufacturer's instructions.

PCR reactions (modified from Delmiglio *et al.*, 2016) are set up in a total volume of 10 µl, as follows:

- i) 1 µl template DNA (see Section B.1.3.1);
- ii) 0.3 µM forward (aw\_F1-flap) and reverse primer (aw\_R3);
- iii) 0.1 µM probe (aw\_LNAprobe);
- iv) 1 mM dNTPs;
- v) 3.5 mM MgCl<sub>2</sub>;
- vi) 0.3 µg bovine serum albumin
- vii) 1 U of Taq polymerase in the appropriate PCR buffer

Using the following thermocycling conditions: 95°C (2 minutes), 35 cycles of 95°C (10 seconds), 59°C (45 seconds).

## C. REQUIREMENTS FOR VACCINES

There are no vaccines available.

## ACKNOWLEDGEMENTS

Photographs courtesy of Qing Hai Fan are reproduced with their permission.

## REFERENCES

- BROTHER ADAM (1968). 'Isle of Wight' or acarine disease: its historical and practical aspects. *Bee World*, **49**, 6–18.
- BRUCE W.A., HENEGAR R.B. & HACKETT K.J. (1991). An artificial membrane for *in vitro* feeding of *Varroa jacobsoni* and *Acarapis woodi*, mite parasites of honey bees. *Apidologie*, **22**, 503–507.
- COLIN M.A., FAUCON J.P., GIANFERT A. & SARRAZIN C. (1979). A new technique for the diagnosis of Acarine infestation in honey bees. *J. Apic. Res.*, **18**, 222–224.
- DAWICKE B.L., OTIS G.W., SCOTT-DUPREE C. & M. NASR (1992). Host preference of the honey bee tracheal mite (*Acarapis woodi* [Rennie]). *Exp. App. Acarol.*, **15**, 83–98.



- DELFINADO-BAKER M. & BAKER E.W. (1982). Notes on honey bee mites of the genus *Acarapis* Hirst (Acari: Tarsonemidae). *Int. J. Acarol.*, **8**, 211–226.
- DELMIGLIO C., FAN Q-H., GEORGE S., WARD L., BUDGE G., FLYNN A. & KUMARASINGHE L. (2016). Development and evaluation of a real-time PCR assay for the detection of *Acarapis woodi* (tracheal mites) in *Apis mellifera*. *Apidologie*, **47**, 691–702.
- SCOTT-DUPREE C.D. & OTIS G.W. (1992). The efficacy of four miticides for the control of *Acarapis woodi* (Rennie) in a fall treatment program. *Apidologie*, **23**, 97–106.
- EISCHEN F.A., PETTIS J.S. & DIETZ A. (1986). Prevention of *Acarapis woodi* infestation in queen honey bees with amitraz. *Am Bee J.*, **126**, 498–500.
- EVANS J.D., PETTIS J.S. & SMITH I.B. (2007). A diagnostic genetic test for the honey bee tracheal mite, *Acarapis woodi*. *J. Apic. Res.*, **46**, 195–197.
- FRAZIER M.T., FINLEY J., HARKNESS W. & RAJOTTE E.G. (2000). A sequential sampling scheme for detecting infestation levels of tracheal mites (Heterostigmata: Tarsonemidae) in honey bee (Hymenoptera: Apidae) colonies. *J. Econ. Entomol.*, **93**, 551.
- GIORDANI G. (1964). Recherches au laboratoire sur *Acarapis woodi* (Rennie), agent de l'acariose des abeilles (*Apis mellifera* L.). Note 3. *Bull. Apic.*, **7**, 43–60.
- GIORDANI G. (1965). Recherches au laboratoire sur *Acarapis woodi* (Rennie), agent de l'acariose des abeilles (*Apis mellifera* L.). Note 4. *Bull. Apic.*, **8**, 159–176.
- GIORDANI G. (1970). Ricerche di laboratorio su *Acarapis woodi* (Rennie), agente dell'acarosi delle api mellifiche (*Apis mellifera* L.) Nota 6. *Ann. Acc. Naz. Agric.*, **90**, 69–76.
- HOOD W.M. & MCCREADIE J.W. (2001). Field tests of the Varroa Treatment Device using formic acid to control *Varroa destructor* and *Acarapis woodi*. *J. Agric. Urban Entomol.*, **18**, 87.
- KOJIMA Y., YOSHIYAMA M., KIMURA K. & KADOWAKI T. (2011). PCR-based detection of a tracheal mite of the honey bee *Acarapis woodi*. *J. Invertebr. Pathol.*, **108**, 135–137.
- LORENZEN K. & GARY N.E. (1986). Modified dissection technique for diagnosis of tracheal mites (Acari: Tarsonemidae) in honey bees (Hymenoptera: Apidae). *J. Econ. Entomol.*, **79**, 1401–1403.
- MILNE P.S. (1948). Acarine disease of bees. *J. UK Ministry Agriculture Fisheries*, **54**, 473–477.
- NAVAJAS M., FOURNIER D., LAGNEL J., GUTIERREZ J. & BOURSO P. (1996). Mitochondrial COI sequences in mites: Evidence for variations in base composition. *Insect Mol. Biol.*, **5**, 281–285.
- OTIS G.W. & SCOTT-DUPREE C.D. (1992). Effects of *Acarapis woodi* on Overwintered Colonies of Honey Bees (Hymenoptera: Apidae) in New York. *J. Econ. Entomol.*, **85**, 40–46.
- PENG Y. & NASR M.E. (1985). Detection of honey bee tracheal mites (*Acarapis woodi*) by simple staining techniques. *J. Invertebr. Pathol.*, **46**, 325–331.
- PETTIS J.S., COX R.L. & WILSON W.T. (1988). Efficacy of fluvalinate against the honey bee tracheal mite, *Acarapis woodi*, under laboratory conditions. *Am. Bee J.*, **128**, 806.
- SAMMATARO D. & NEEDHAM G.R. (1996). Host-seeking behaviour of tracheal mites (Acari: Tarsonemidae) on honey bees (Hymenoptera: Apidae). *Exp. Appl. Acarol.*, **20**, 121–136.
- SAMMATARO D., DE GUZMAN L., GEORGE S., OCHOA R. & OTIS G. (2013). Standard methods for tracheal mite research. *J. Apic. Res.*, **52**, 1–20.
- TOMASKO M., FINLEY J., HARKNESS W. & RAJOTTE E. (1993). A sequential sampling scheme for detecting the presence of tracheal mite (*Acarapis woodi*) infestations in honey bee (*Apis mellifera* L.) colonies. *Penn. State Agric. Exp. Stn Bull.*, **871**.

WILSON W.T., PETTIS J.S, HENDERSON C.E. & MORSE R.A. (1997). Tracheal mites. *In: Honey Bee Pests, Predators and Diseases*, Third Edition. AI Root publishing, Medina, Ohio, USA, pp 255–277.

\*  
\* \*

**NB:** At the time of publication (2022) there was no OIE Reference Laboratory for *acarapisosis of honey bees* (infestation of honey bees with *Acarapis woodi*) (please consult the OIE Web site for the most up-to-date list: <https://www.woah.org/en/what-we-offer/expertise-network/reference-laboratories/#ui-id-3>).

**NB:** FIRST ADOPTED IN 1989 AS ACARIASIS OF HONEY BEES. MOST RECENT UPDATES ADOPTED IN 2022.